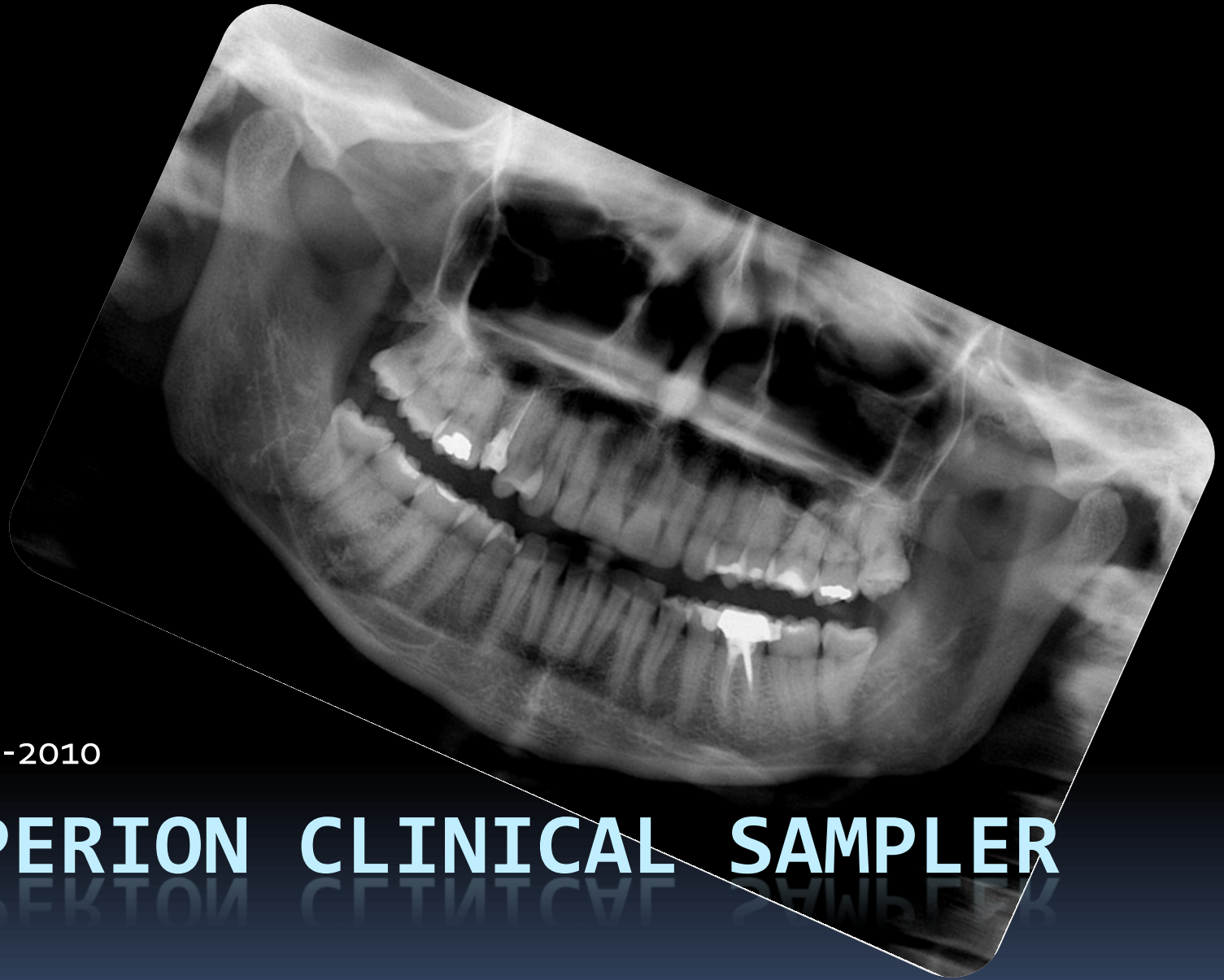
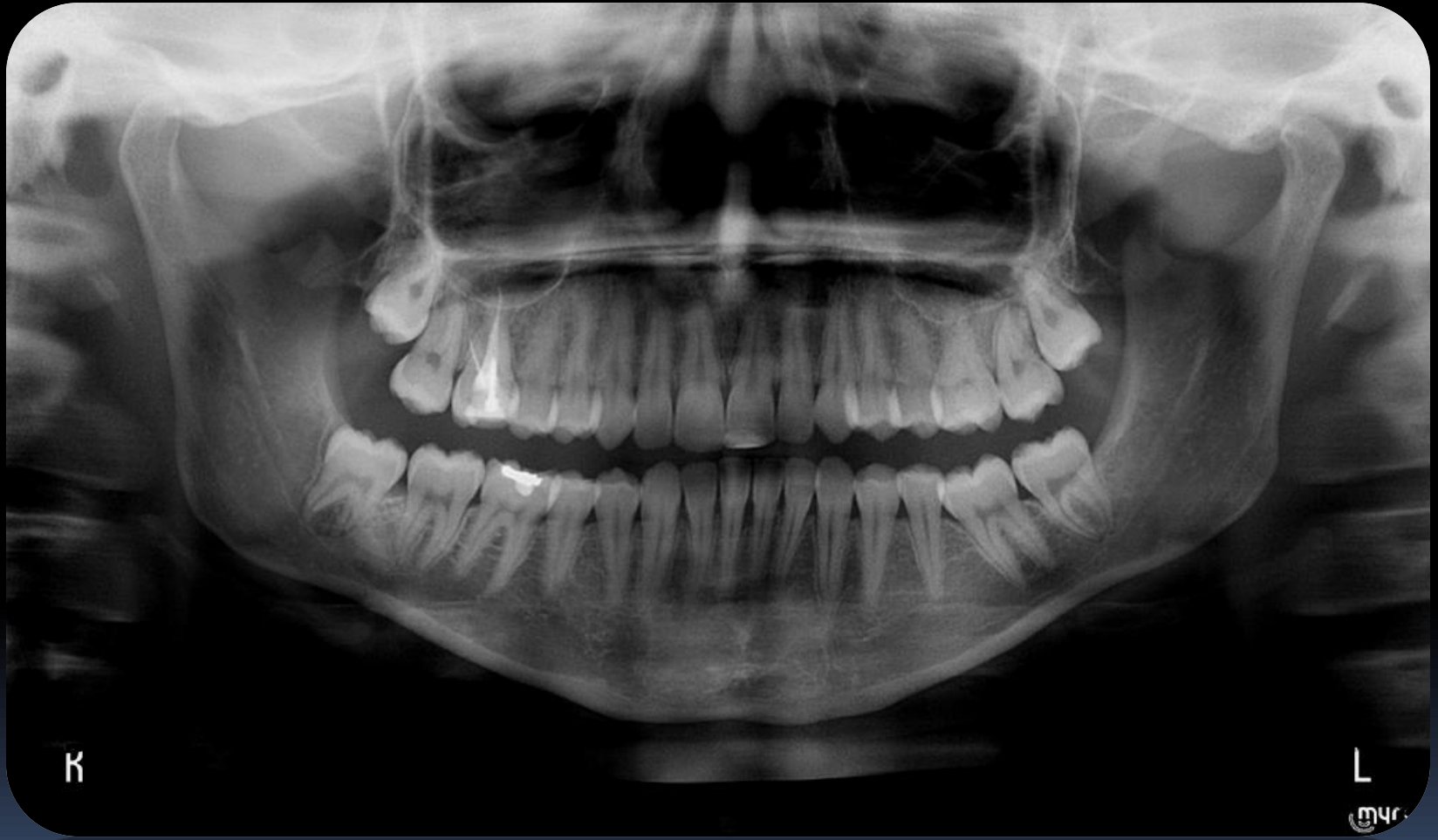
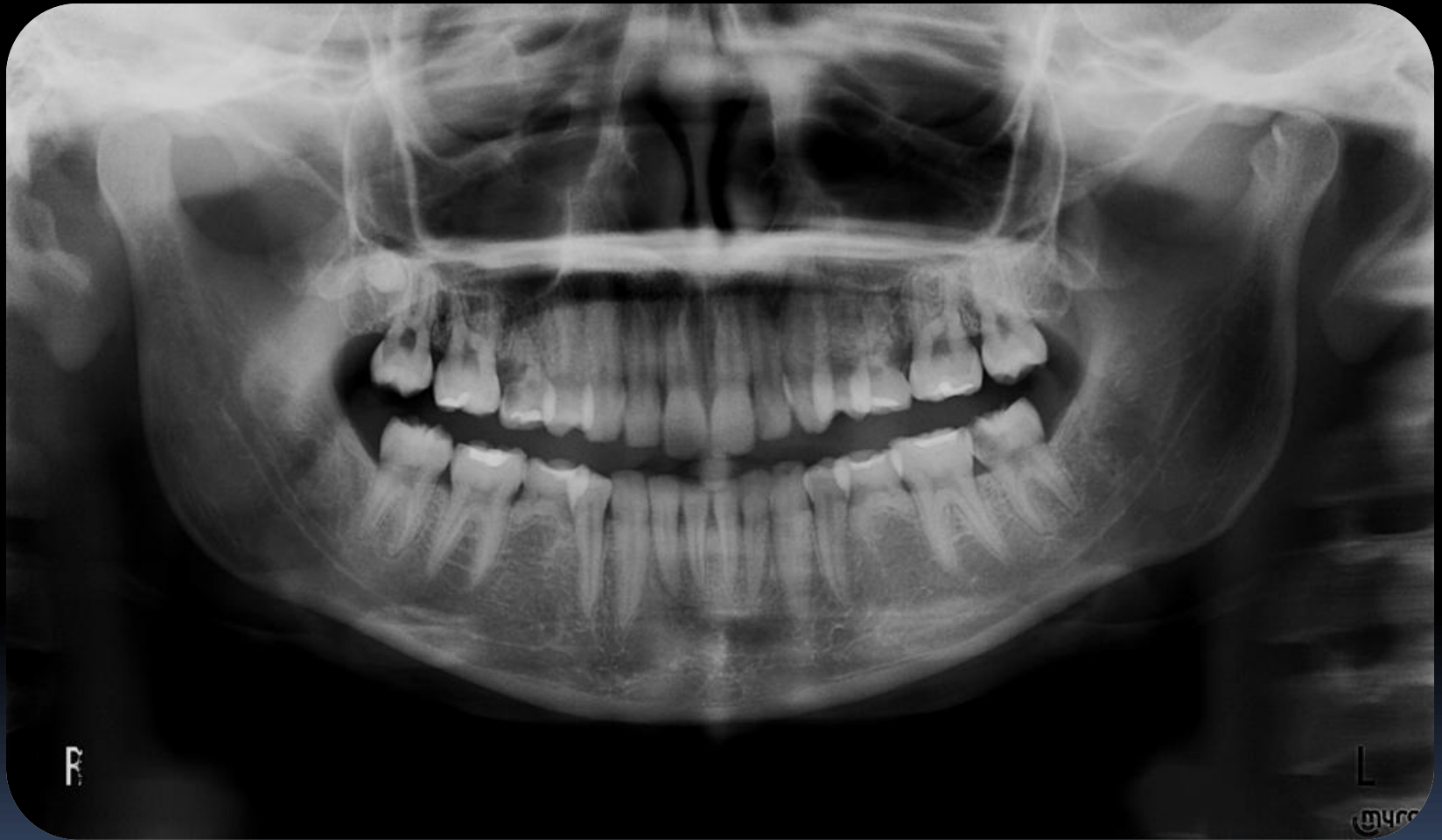10 – 05 - 2010

# HYPERION CLINICAL SAMPLER

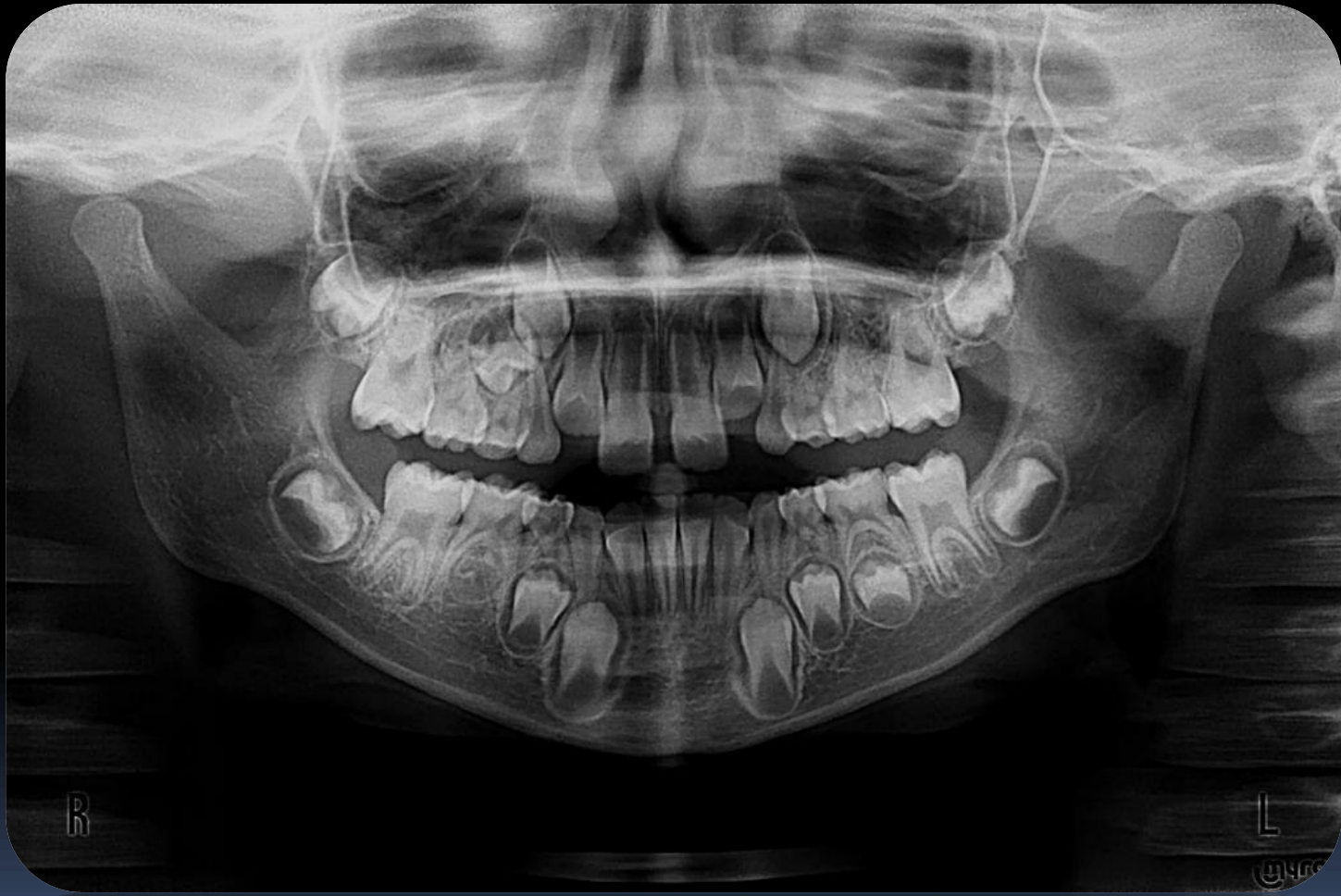# Adult



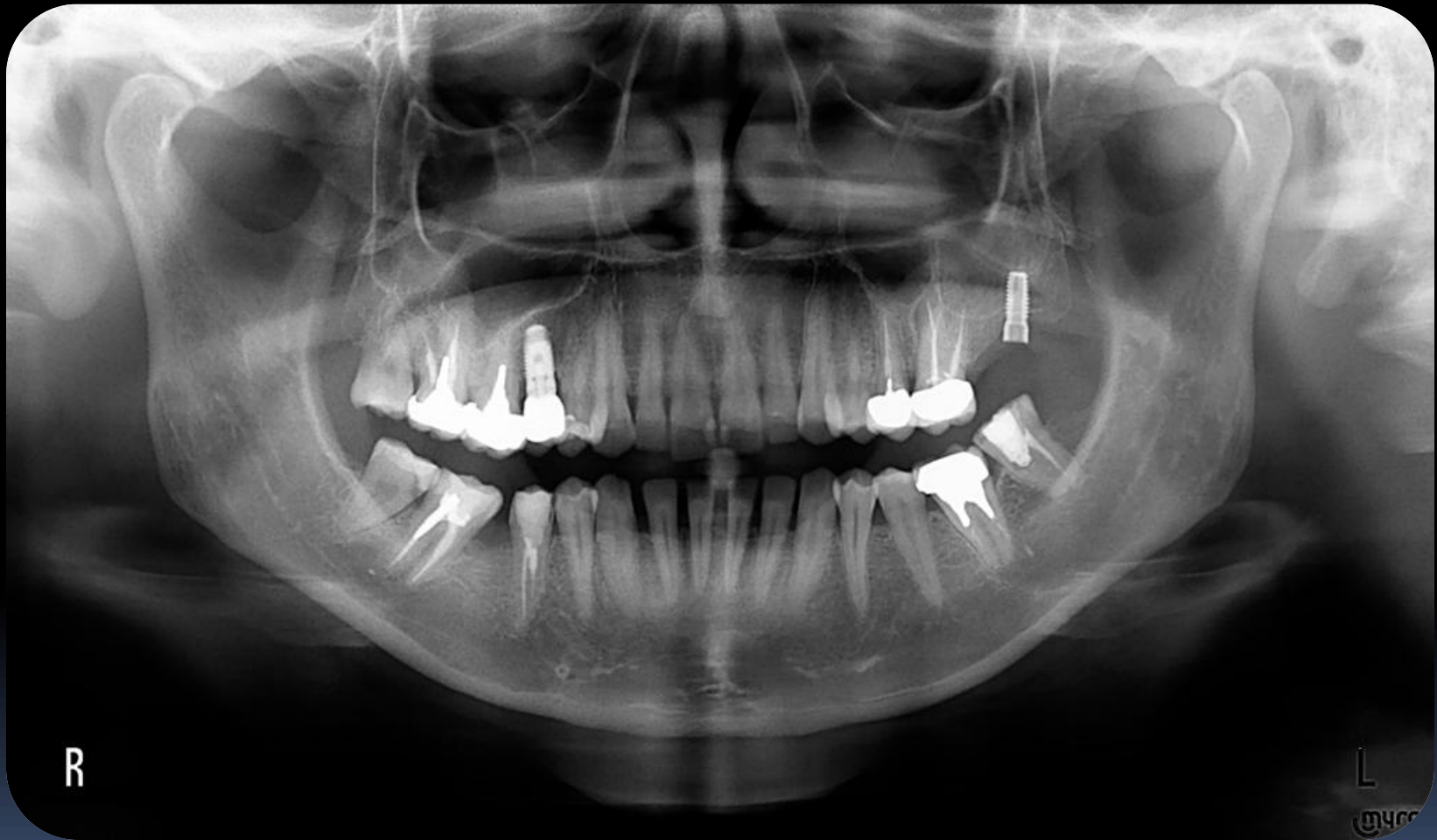# Young



# Child

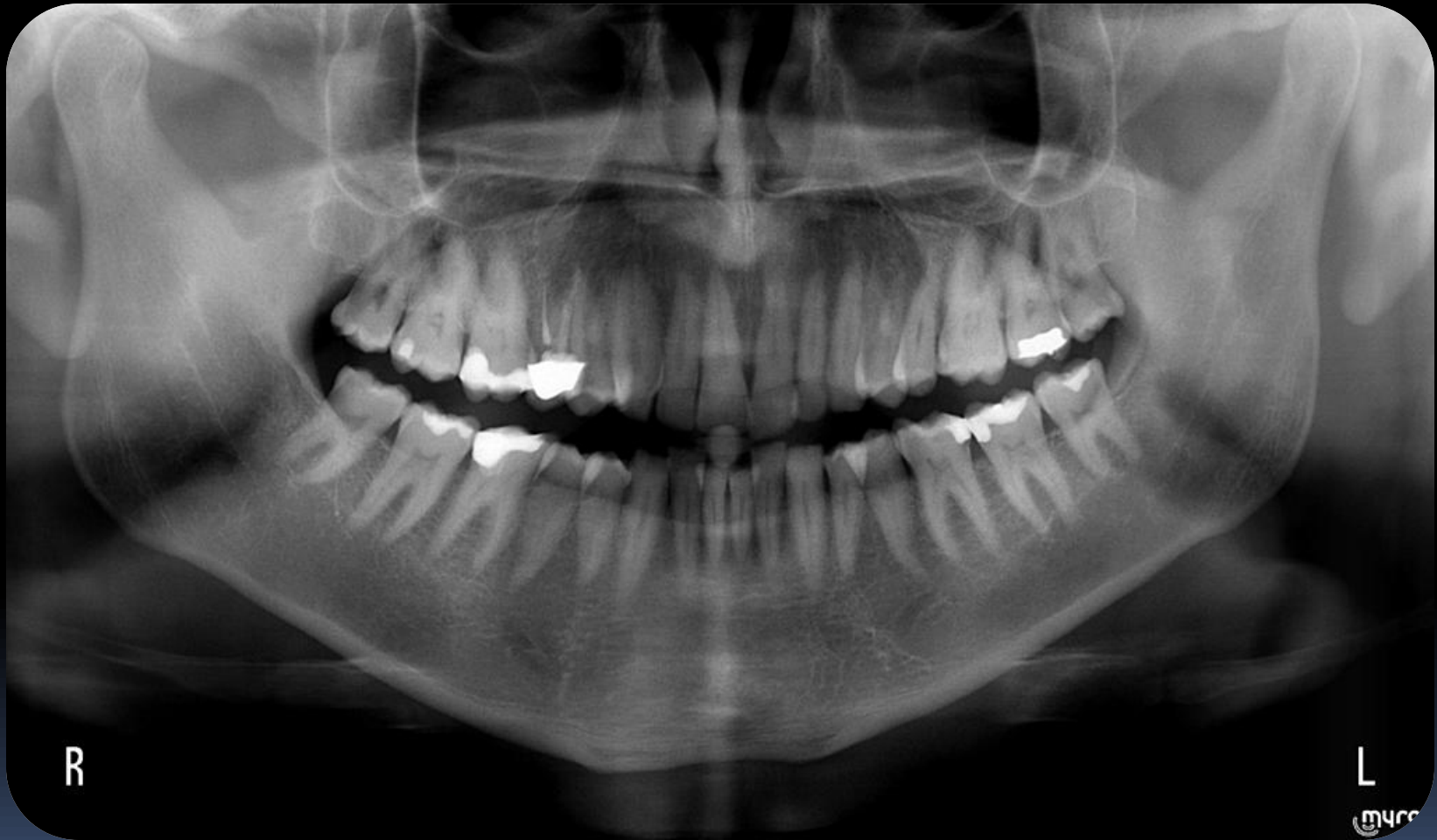

# Adult with implants





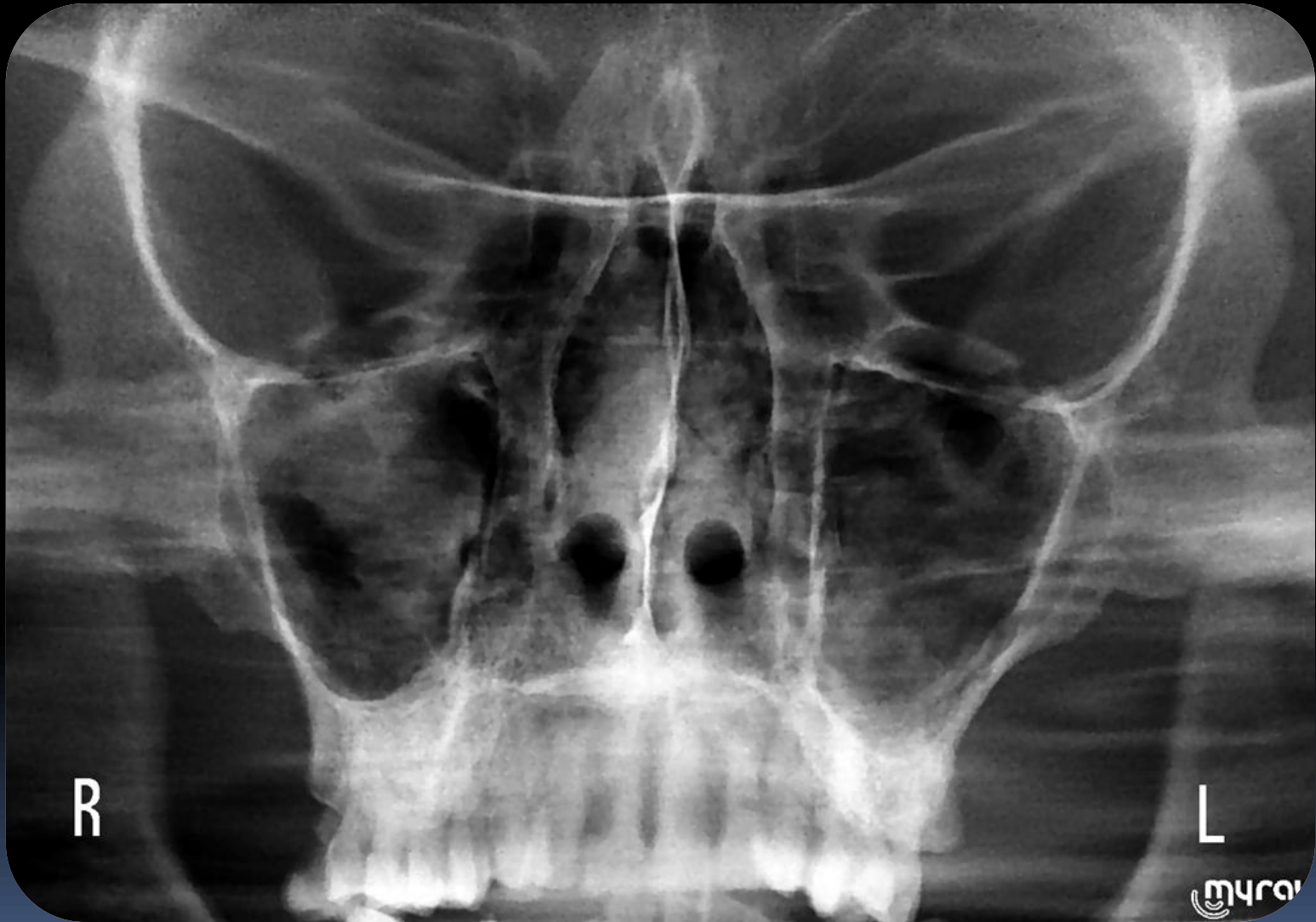# Large Adult



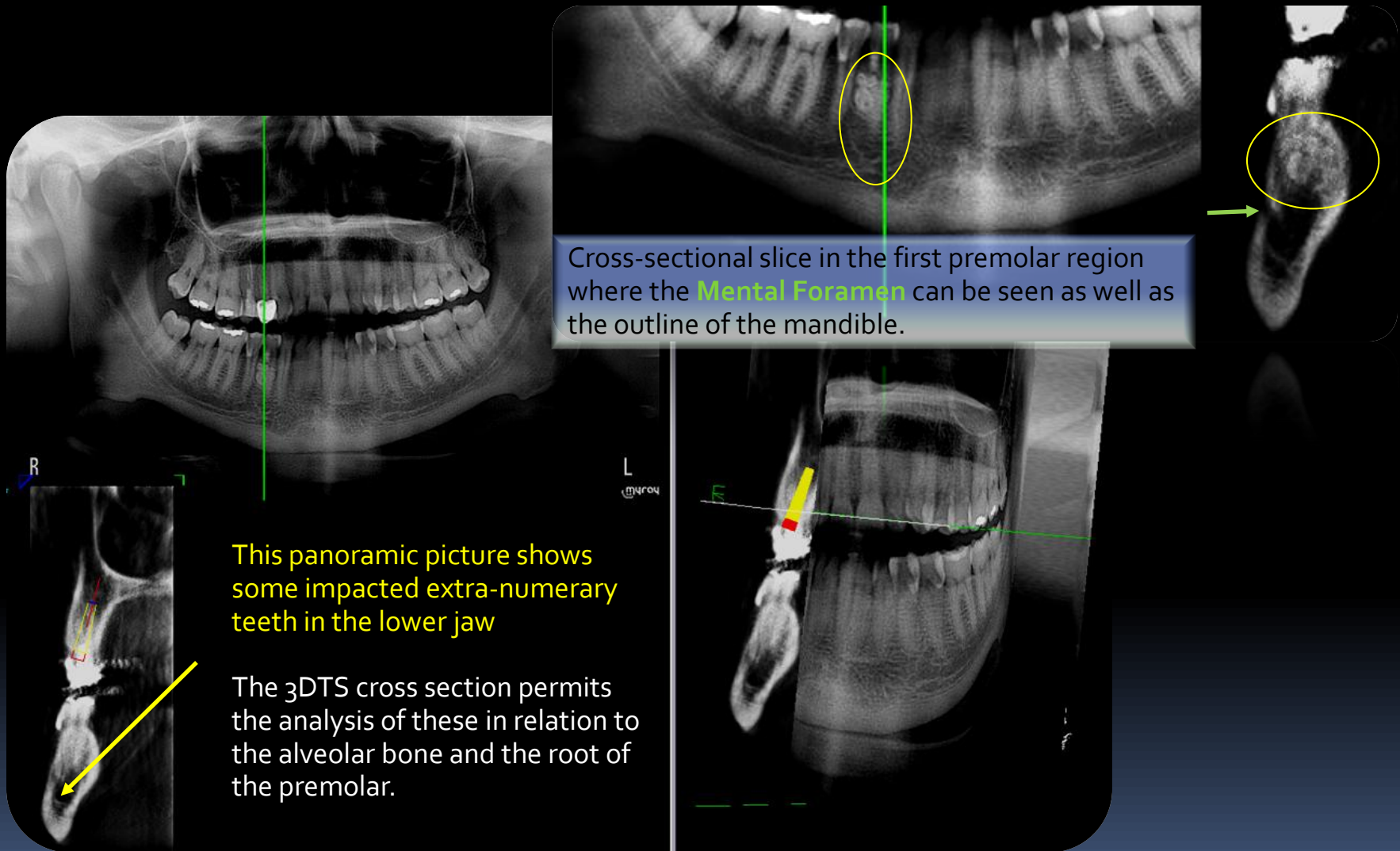
R

L

# Maxillary Sinus

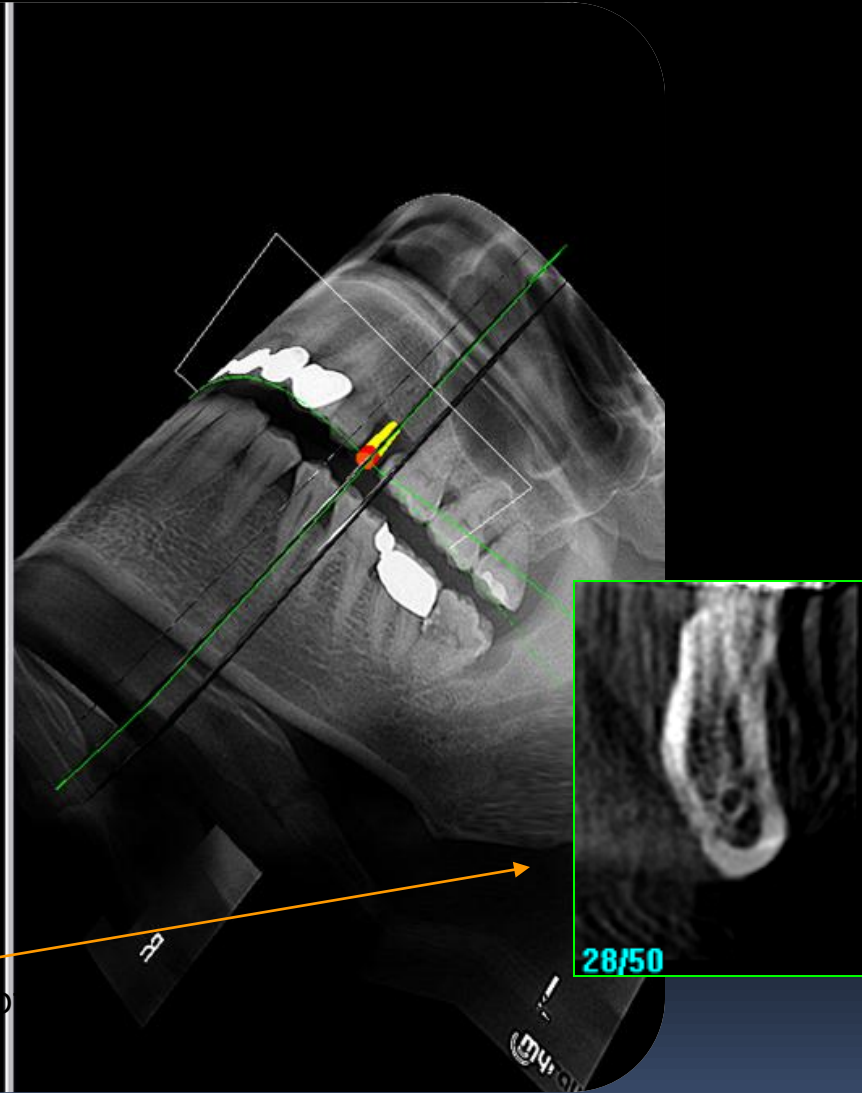
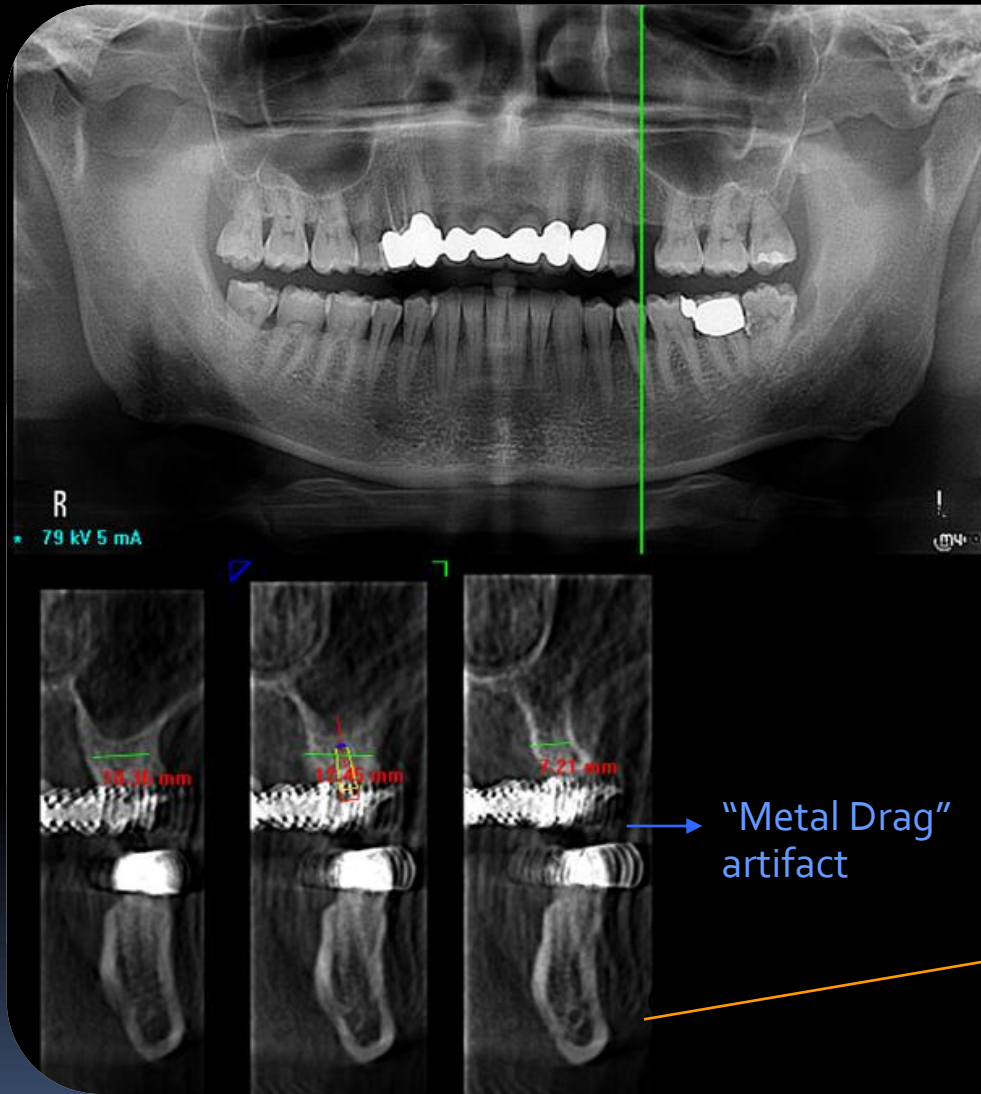


# Impacted teeth and bone evaluation

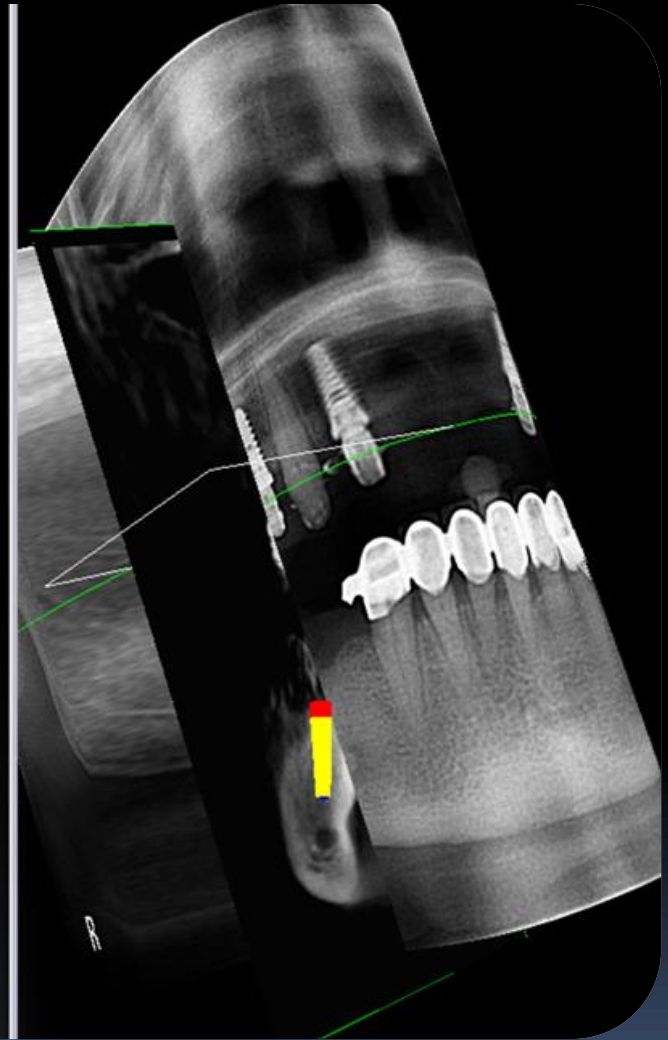
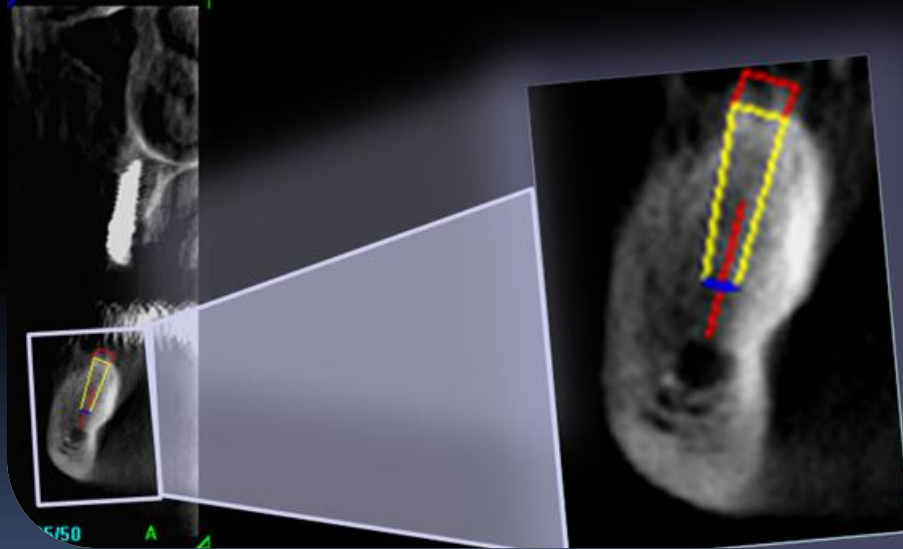
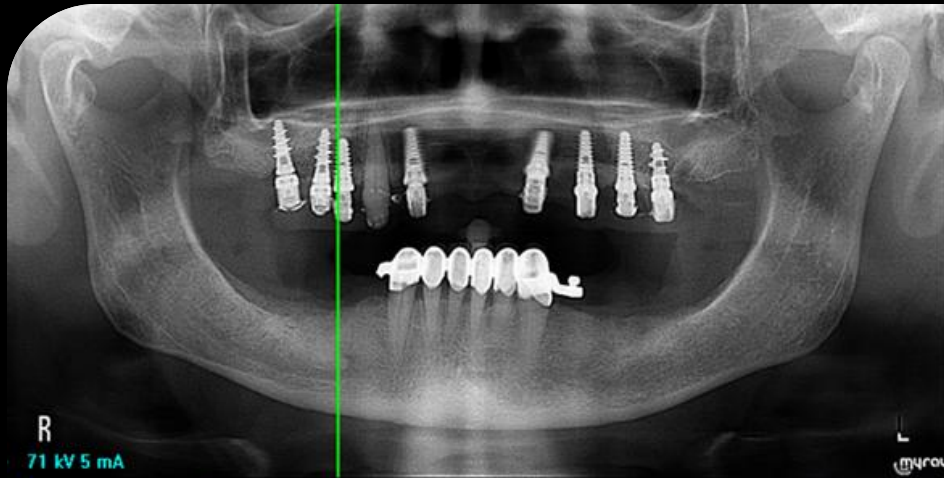




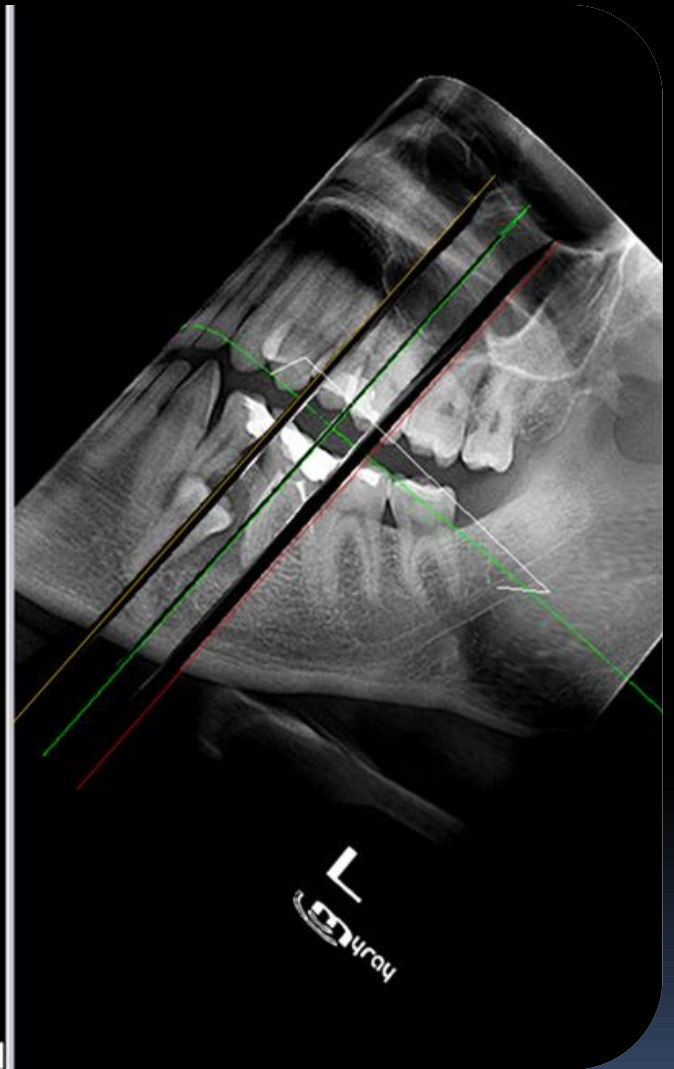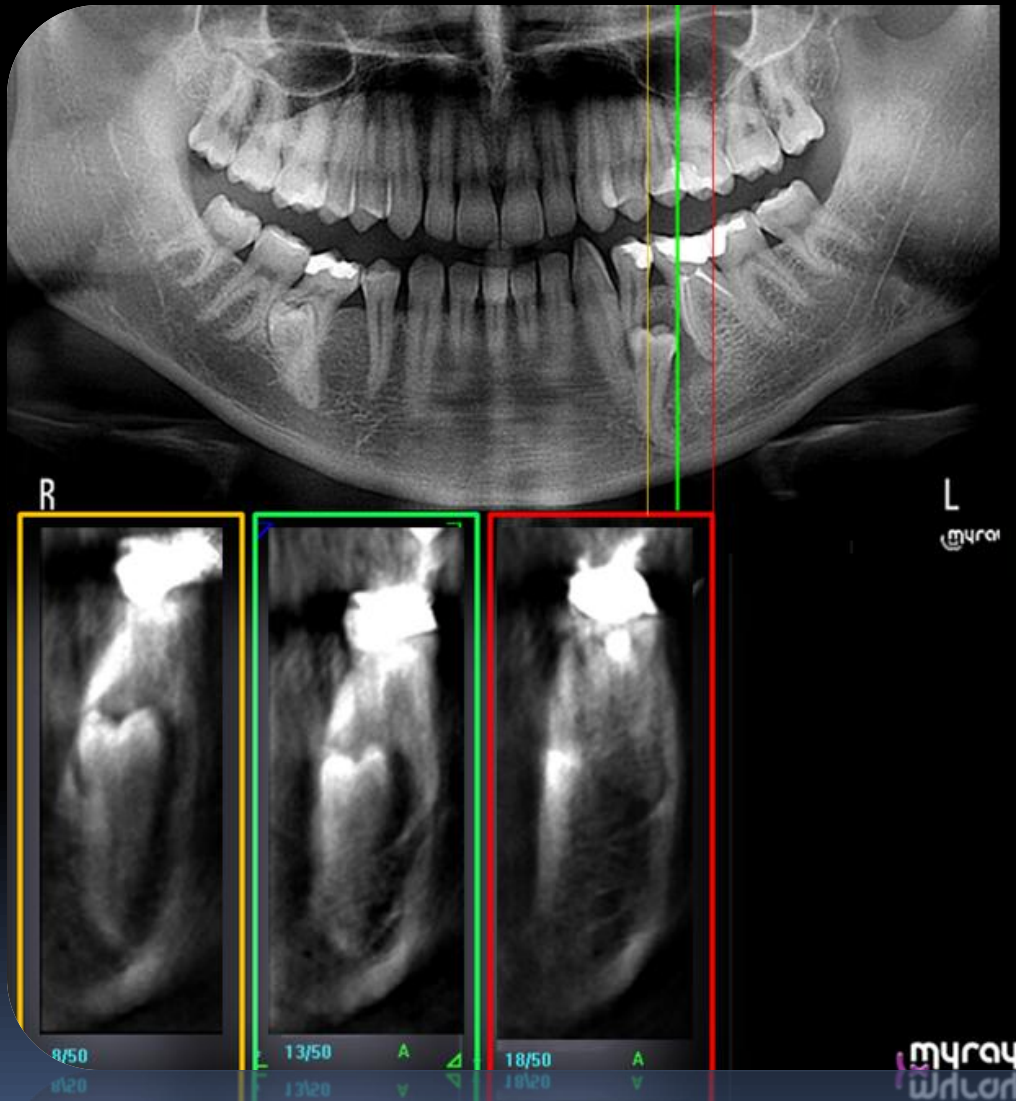
# Implant planning



# Implant Planning



# Impacted tooth in deciduous dentition





# Sample of pre/post surgery imaging

